



## Case Report

# Unraveling the enigma: A case report

K. K. Lahari<sup>1</sup>, Aditya Ganesh Parik<sup>2</sup>, Priya Horatti<sup>3</sup>, Amit Kashinath Pachalg<sup>3</sup>, Roshni V. Namboodiri<sup>3</sup>, Sindhu U. Muktamath<sup>4</sup>

<sup>1</sup>Department of Conservative Dentistry and Endodontics, SDM Dental College, <sup>2</sup>Department of Conservative Dentistry and Endodontics, SDM Dental College and Hospital, <sup>3</sup>Department of Conservative Dentistry and Endodontics, SDM College of Dental Sciences and Research Centre, Dharwad, <sup>4</sup>Department of Conservative Dentistry and Endodontics, Manipal College of Dental Science, Manipal, Karnataka, India.



### \*Corresponding author:

K. K. Lahari,  
Department of Conservative Dentistry and Endodontics, SDM Dental College, Dharwad, Karnataka, India.

[laharikaje@gmail.com](mailto:laharikaje@gmail.com)

Received : 04 May 2022  
Accepted : 13 August 2022  
Published : 24 November 2022

DOI  
[10.25259/JRDE\\_4\\_2022](https://doi.org/10.25259/JRDE_4_2022)

Quick Response Code:



## ABSTRACT

The purpose of this case report is to emphasize the importance of cone-beam computed tomography (CBCT) and dental operating microscope for endodontic treatment on mandibular second premolar with three separate roots. In endodontics, the possible existence of extra canals must be considered before endodontic treatment is instituted. A wide morphological variation of the mandibular second premolar is known to exist. The incidence of a three-rooted mandibular second premolar is approximately 0.4%. A 43-year-old female patient was referred for endodontic treatment on the mandibular second premolar. IOPA revealed three roots, and hence for confirmation, a CBCT image was taken and root canal treatment was performed under an operating microscope for enhanced visualization. This case report describes the successful endodontic treatment of a mandibular second premolar with three separate roots and canals filled using gutta-percha and AH Plus. Clinical significance: Conventional endodontic treatment can be performed on a tooth with complex root canal morphology using an operating microscope.

**Keywords:** Variation in a root canal, Cone beam computed tomography, Magnification, Isolation

## INTRODUCTION

Mandibular premolars have always been reputed to have aberrant anatomy. A wide morphological divergence of the root canal system is known to exist. The varying number of root canals in different teeth, their anatomy, and interconnections have been studied and reported in several studies.<sup>[1]</sup> Vertucci *et al.* showed that the second premolar had only one root canal at the apex in 97.5% of the teeth studied and two canals in only 2.5%, three root canals were scarce.<sup>[2]</sup> Zillich and Dowson reported 11.7% occurrence of two canals and 0.4% of three canals.<sup>[3]</sup>

The presence of root canal aberrations is frequently recognized after root canal therapy when an additional or branching canal appears to be (partly) filled with root canal sealer.

Although intraoral periapical radiograph and intracanal visualization with the naked eye remain a primary method of treatment, the use of the cone-beam computed tomography (CBCT) and dental operating microscope and fiberoptic endoscope allows to a better view of canal morphology as well as canal preparations.<sup>[1]</sup>

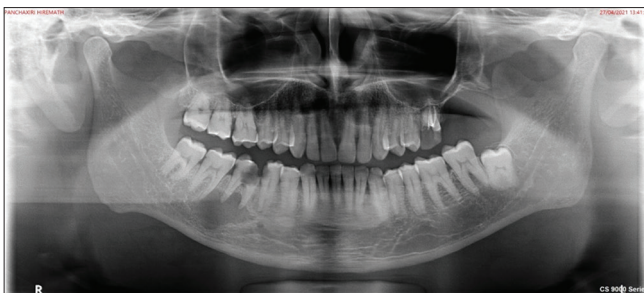## CASE REPORT

A 43-year-old male with a non-contributory medical history was referred to SDM Dental College and Hospital, Dharwad for endodontic treatment on the right mandibular second premolar. The

chief complaint of the patient was “pain in the lower right back teeth.” Clinical examination revealed distal caries in the right mandibular second premolar tooth 45. Radiographic examination showed normal periodontium and more than one root canal was suspected in the tooth [Figure 1]. The tooth was diagnosed with irreversible pulpitis based on clinical and radiographic findings and it was decided to undergo endodontic therapy for the lower right second premolar. Orthopantomogram taken for the diagnostic purpose revealed the presence of two root canals and a third root canal was suspected due to an abnormal dimension in the root. RVG taken at different angulations during the endodontic procedure could not confirm the number of roots or root canals. Hence, to ascertain this rare and complex root canal anatomy of the tooth in a three-dimensional manner, dental imaging with the help of a CBCT was planned. Informed consent from the patient was obtained and a CBCT scan of the mandible was performed using the dental software Carestream (GE Healthcare, Milwaukee, WI). A three-dimensional image of the mandible was obtained. The involved tooth was focused, and the morphology was obtained in transverse, axial, and sagittal sections of 0.5 mm thickness, along with three-dimensional reconstructed images [Figure 2].

Informed consent was obtained from the patient for endodontic treatment of the involved teeth. The tooth was anesthetized using a local anesthetic (2% Lignocaine with 1:100,000 epinephrine) solution by way of the inferior nerve block of the right side. Under rubber dam isolation, the access cavity was prepared with round diamond burs in a high speed airrotor handpiece.

Access preparation was initiated on tooth number 45 and on entry into the pulp chamber, two canal orifices were found. Hence, to ascertain this rare and complex root canal anatomy of the tooth, it was observed under a dental operating microscope (OPMI pico Dental Microscope, Zeiss, Oberkochen, Germany). For deeper exploration and location of canal orifices, finer diamond coated tips such as ETBD tip (Satelec acteon group) were used, two orifices on the buccal, and one orifice on the lingual side were located [Figure 3].



**Figure 1:** OPG image showing carious mandibular right second premolar.

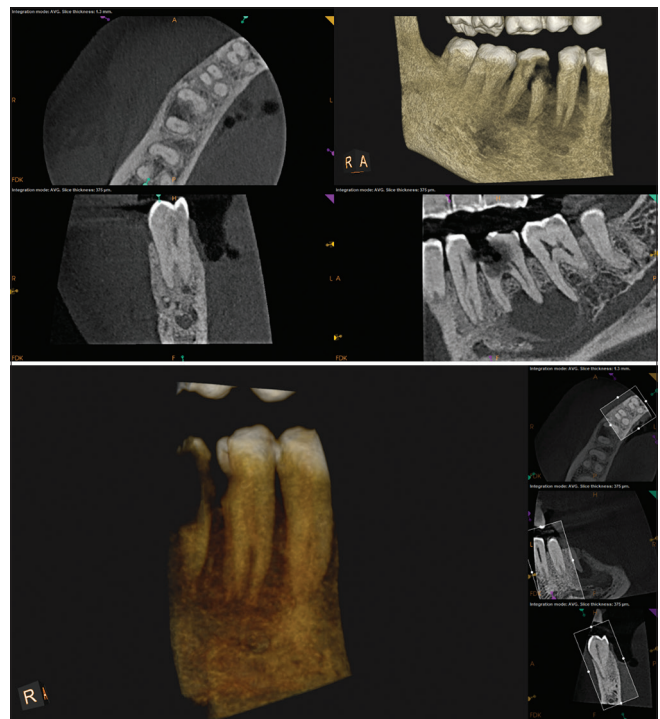Working length was established with the use of an apex locator (Root ZX, J. Morita Inc., USA) and confirmed by a radiograph. The canals of teeth were cleaned and shaped with hand K-files size 20# (Maillefer Dentsply, Baillaigues, Switzerland) and rotary Hyflex CM files (Coltene/Whaledent, Allstatten, Switzerland) were used up to size #0.04/25 in mesiobuccal, distobuccal, and lingual canal. The canals were irrigated with 3% sodium hypochlorite during instrumentation and 17% EDTA at the end of instrumentation.

After a final rinse with normal saline, canals were dried and obturated with gutta-percha and AH plus sealer (Dentsply, De Trey, Konstanz, Germany) using the lateral compaction method [Figure 4].

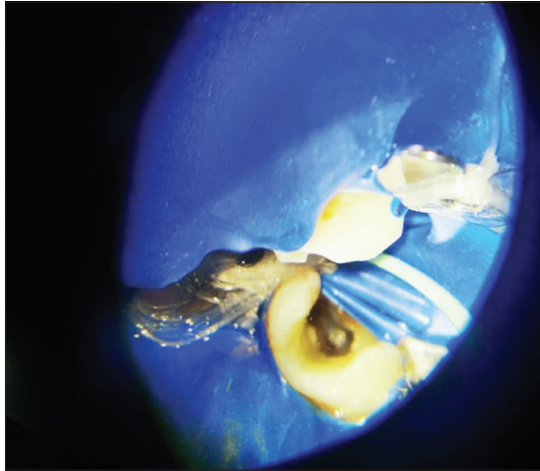
## DISCUSSION

Since 1870, the literature reveals a periodic renewal of the interest in the root canal morphology of teeth to learn more about them to improve endodontic techniques and to obtain success in the treatment.<sup>[4]</sup> Different methods have been used by many investigators to identify tooth morphology, topography, curvature, ramifications of the mail root canal, diameters, localization, and several foramina and apical deltas.<sup>[5]</sup>

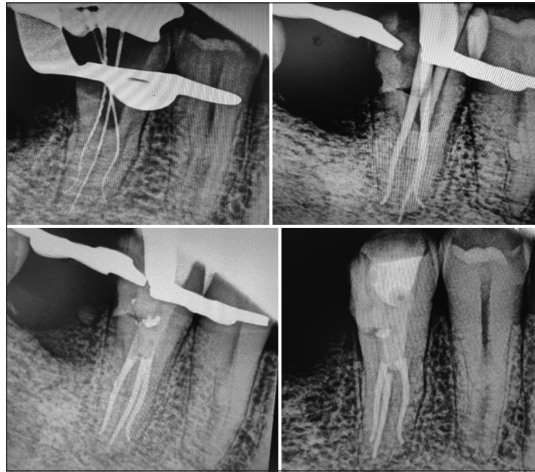
The unpredictability of the root canal system represents a challenge to both endodontic diagnosis and also for further treatment. The primary step in root canal treatment is the identification of the internal morphology and this can



**Figure 2:** CBCT image showing 3 roots in the right mandibular 2<sup>nd</sup> premolar.



**Figure 3:** Image showing three orifices taken through operating microscope (OPMI pico Dental Microscope, Zeiss, Oberkochen, Germany).



**Figure 4:** RVG image showing working length, master cone, and obturation and 3-month follow-up of mandibular right 2<sup>nd</sup> premolar.

be accomplished by proper pre-operative radiographs.<sup>[1]</sup> Radiographically, a root canal may not be clearly evident as there may be a sudden narrowing of the canal space as it divides further termed as “fast break” which should be taken into consideration while assessing the pre-operative radiographs.<sup>[6,7]</sup> If the root canal abruptly seems to straighten or broaden or if the course cannot be traced the presence of a second canal in the same root or of a canal in another root superimposed on the first one because of the radiographic projection should be suspected and anticipated.<sup>[8]</sup>

The anatomical landmarks in the pulp chamber floor also help to identify or give an indication of supplementary root canals or root canal aberrations along with the good illumination magnification also makes the treatment easier.<sup>[1]</sup> In the present case report, it was not possible to detect the

orifice of the additional lingual canal using methylene blue dye.

The study done by Carr and Murgel states that additional canals can be located by various methods such as loupes or microscope and visual enhancement by fiber optics, use of sodium hypochlorite bubble technique, and staining.<sup>[9]</sup>

In this case, an operating microscope was used to enhance visualization and locate the canal orifice.

After working lengths were determined using an apex locator, it was confirmed by radiography to achieve more reliable treatment results. The lateral condensation technique was used for obturation.

In complicated cases, the intraoperative use of CBCT can assist the clinician in ensuring a safer procedure and a more predictable treatment outcome. However, the use of ionizing radiation should always comply with the principle of As Low As Reasonably Achievable to minimize the patient’s exposure to radiation.<sup>[10]</sup>

In the present case report, conventional periapical radiographs could not provide sufficient information on the location of three orifices. Hence, the use of CBCT was necessary and proved to be vital in successfully locating the orifices.

Sabala *et al.* reported that abnormal morphology of the roots is bilateral in almost 90% of the cases and the rarer the prevalence, the higher the odds of bilateral occurrence.<sup>[11]</sup>

In the present case, the CBCT image revealed bilateral abnormal root morphology on both the second premolar teeth.

Although it is very rare for a mandibular second premolar to have three roots, each case should be carefully examined radiographically and clinically to locate all the root canals with the use of additional magnification.

## CONCLUSION

Thorough knowledge of the normal anatomy of the root canals of every tooth is a must for any endodontic procedure. However, there is always a chance that the canal anatomy may vary. In this case, the location of the orifice was other than normal which led to other investigations. CBCT has definitely helped in diagnosing the aberrant anatomy of the mandibular second premolar. The use of a microscope has helped in rendering proper and successful treatment for the tooth.

## Declaration of patient consent

The authors certify that they have obtained all appropriate patient consent.

### Financial support and sponsorship

Nil.

### Conflicts of interest

There are no conflicts of interest.

### REFERENCES

1. De Moor RJ, Calberson FL. Root canal treatment in a mandibular second premolar with three root canals. *J Endod* 2005;31:310-3.
2. Vertucci F, Seelig A, Gillis R. Root canal morphology of the human maxillary second premolar. *Oral Surg Oral Med Oral Pathol* 1974;38:456-64.
3. Zillich R, Dowson J. Root canal morphology of mandibular first and second premolars. *Oral Surg Oral Med Oral Pathol* 1973;36:738-44.
4. Shah S, Mistry K, Chokshi D, Idnani B, Parmar N, Buch A. Mandibular second premolar with two roots and two canals. *BUJOD* 2014;4:81.
5. Pineda F, Kuttler Y. Mesiodistal and buccolingual roentgenographic investigation of 7,275 root canals. *Oral Surg Oral Med Oral Pathol* 1972;33:101-10.
6. Theruvil R, Ganesh C, George AC. Endodontic management of a maxillary first and second premolar with three canals. *J Conserv Dent JCD* 2014;17:88.
7. Slowey RR. Root canal anatomy: Road map to successful endodontics. *Dent Clin North Am* 1979;23:555-73.
8. Sieraski SM, Taylor GN, Kohn RA. Identification and endodontic management of three-canal maxillary premolars. *J Endod* 1989;15:29-32.
9. Carr GB, Murgel CA. The use of the operating microscope in endodontics. *Dent Clin* 2010;54:191-214.
10. Brown J, Jacobs R, Levring Jäghagen E, Lindh C, Baksi G, Schulze D, *et al.* Basic training requirements for the use of dental CBCT by dentists: A position paper prepared by the European academy of dentomaxillofacial radiology. *Dentomaxillofac Radiol* 2014;43:20130291.
11. Sabala CL, Benenati FW, Neas BR. Bilateral root or root canal aberrations in a dental school patient population. *J Endod* 1994;20:38-42.

**How to cite this article:** Lahari KK, Parik AG, Horatti P, Pachalg AK, Namboodiri AV, Muktamath SU. Unraveling the enigma: A case report. *J Restor Dent Endod* 2021;1:59-62.